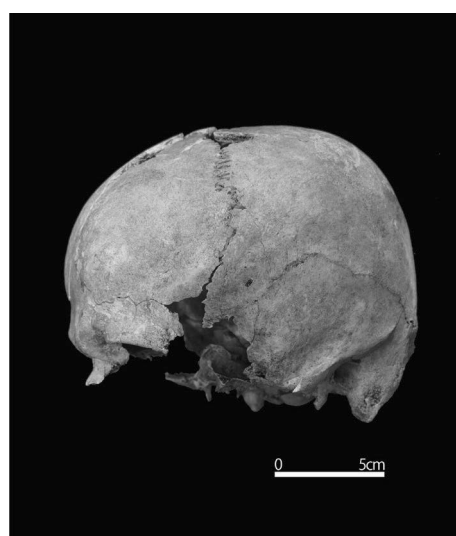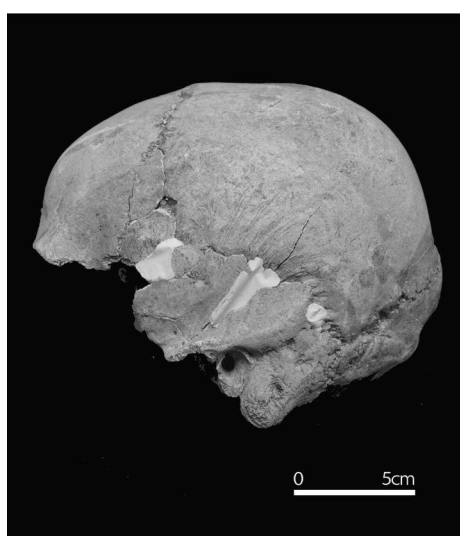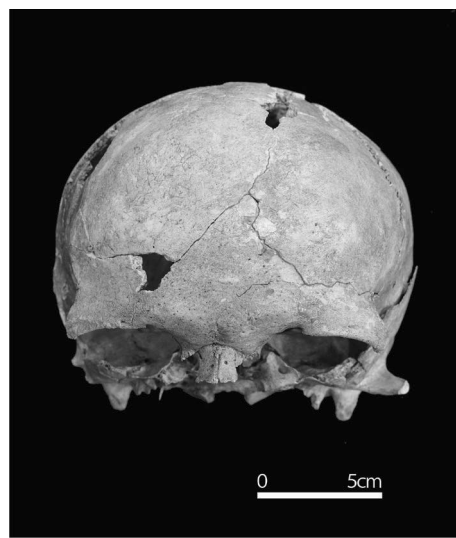
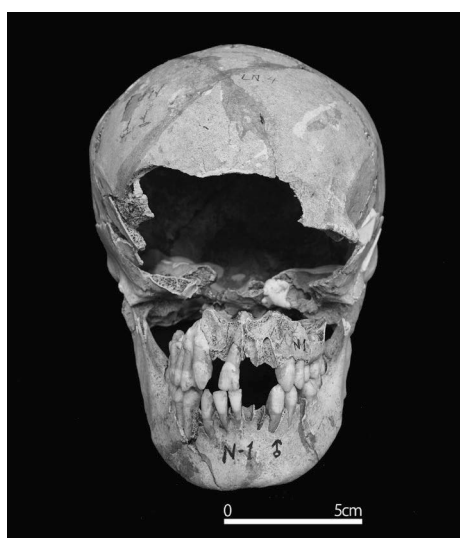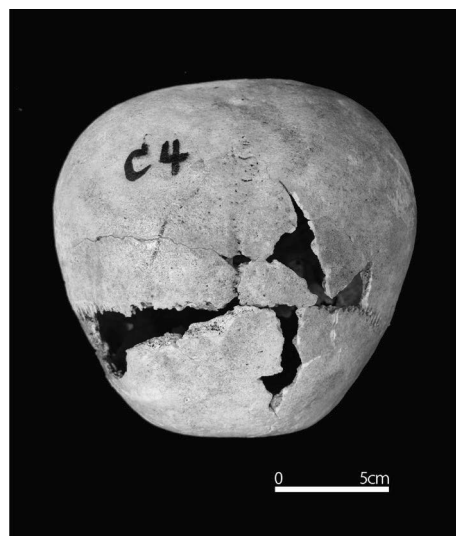


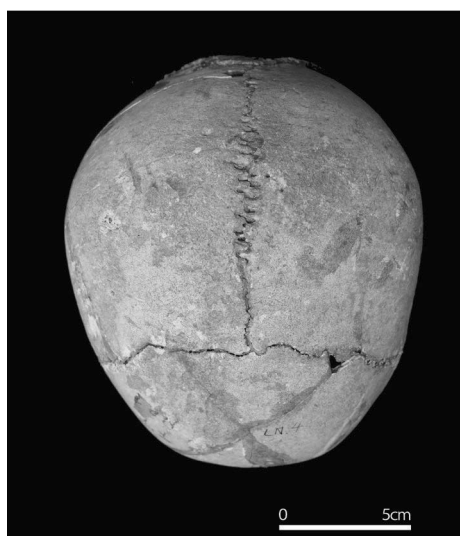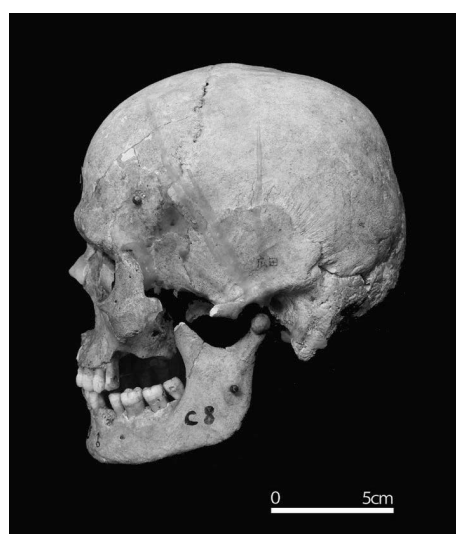
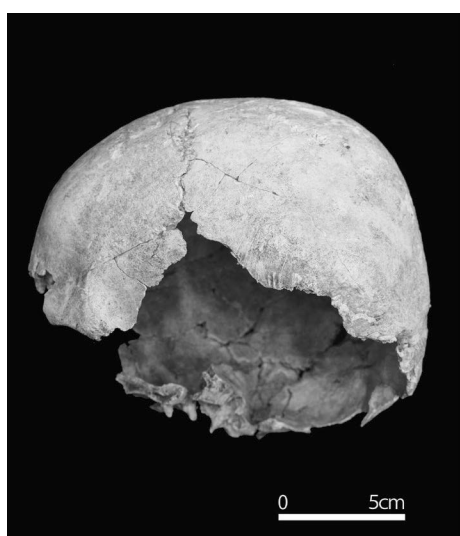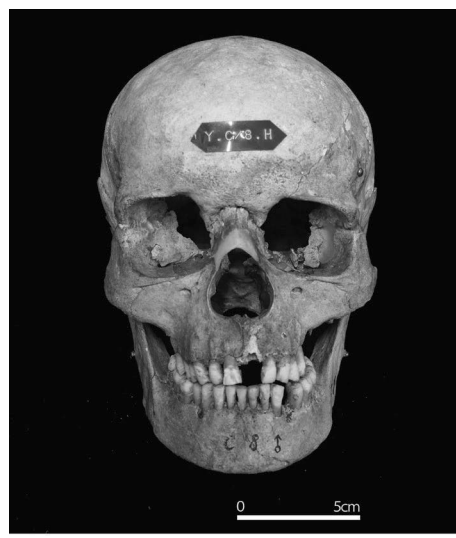
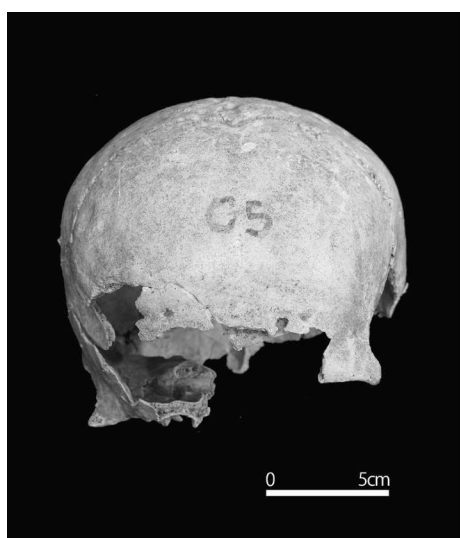
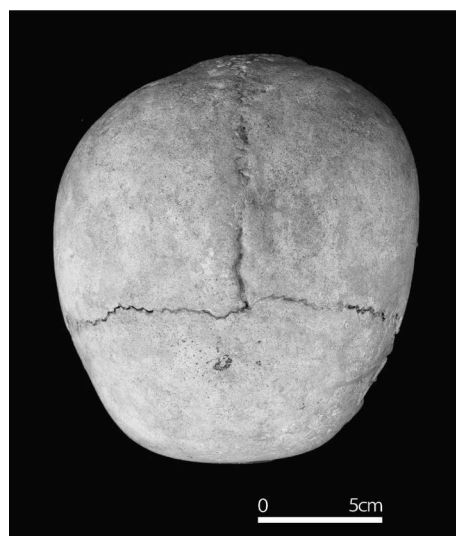

広田遺跡
出土人骨写真図版



N1 号人骨

C 地区 4 号人骨

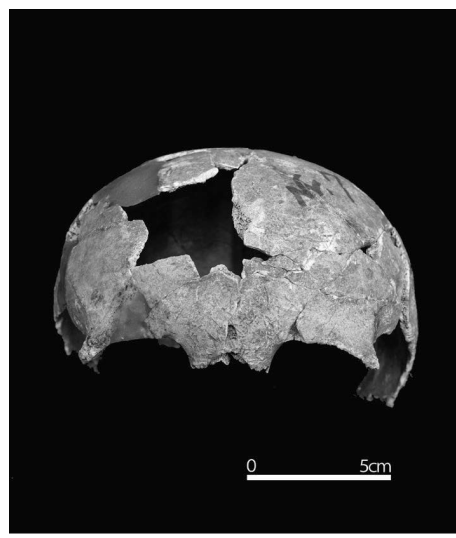
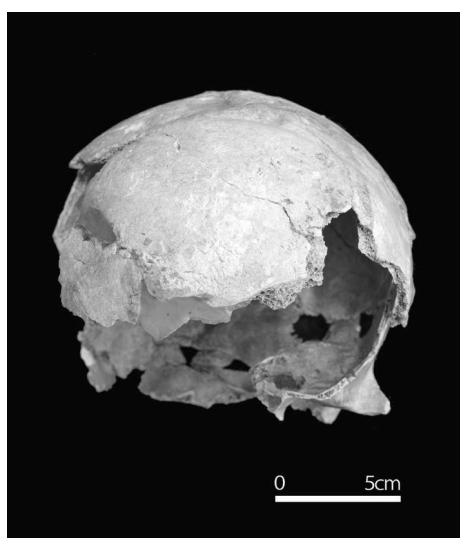
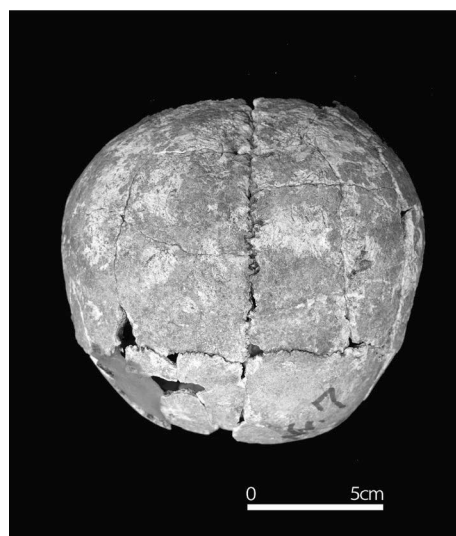
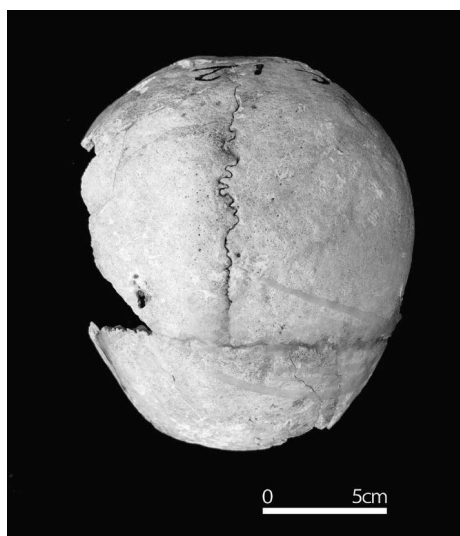
写真 1



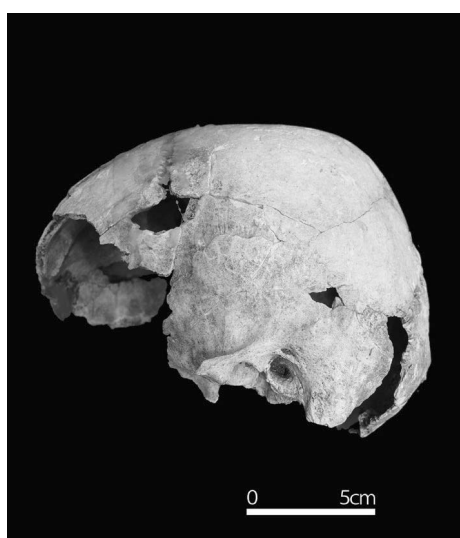C 地区 5 号人骨

C 地区 8 号人骨

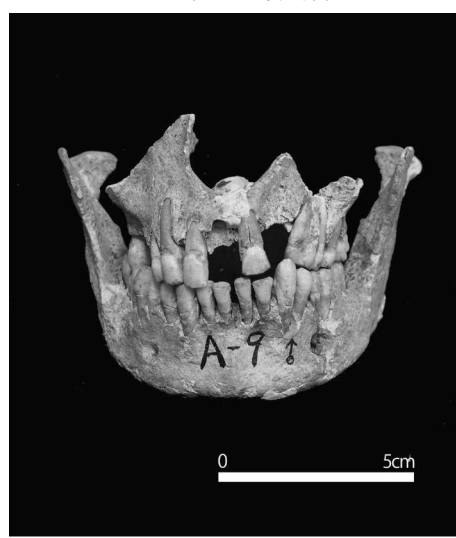
写真 2



A 地区 7 号人骨

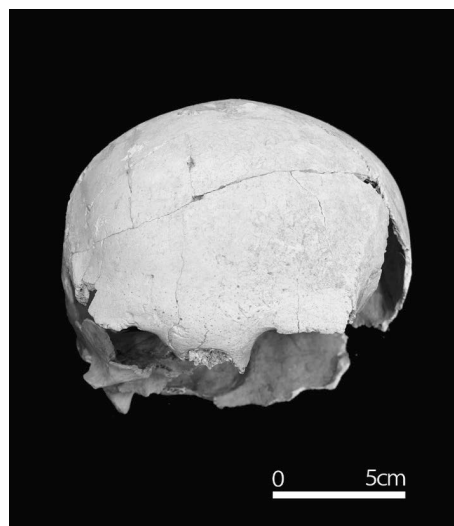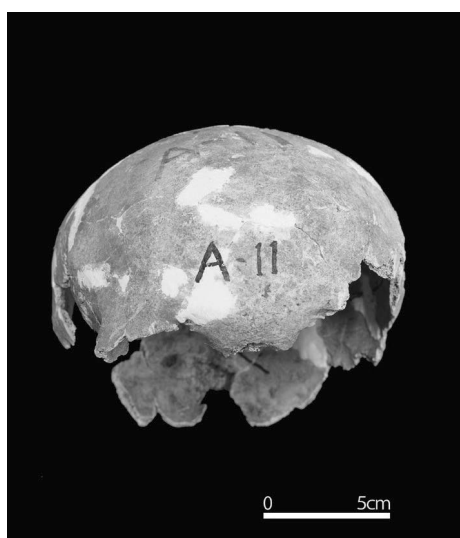
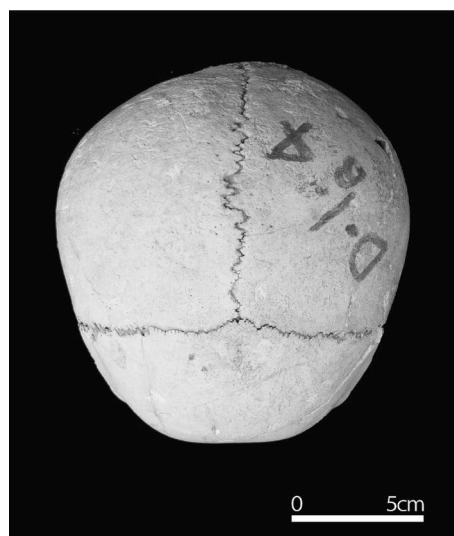
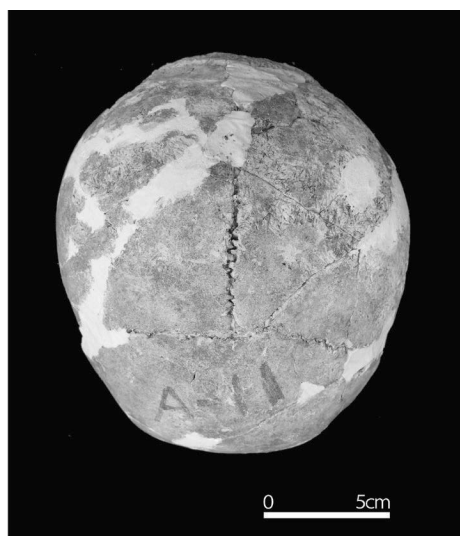


C 地区 12 号人骨

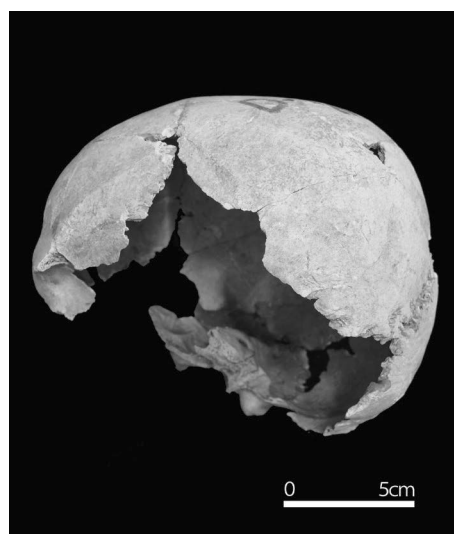


A 地区 9 号人骨

写真 3

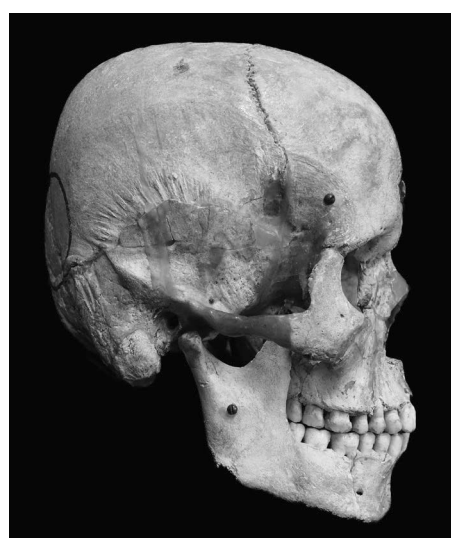
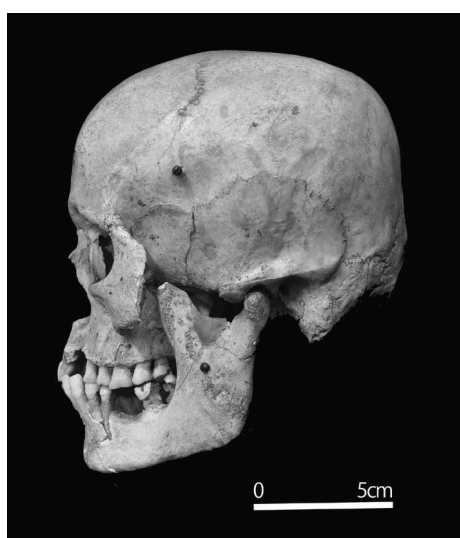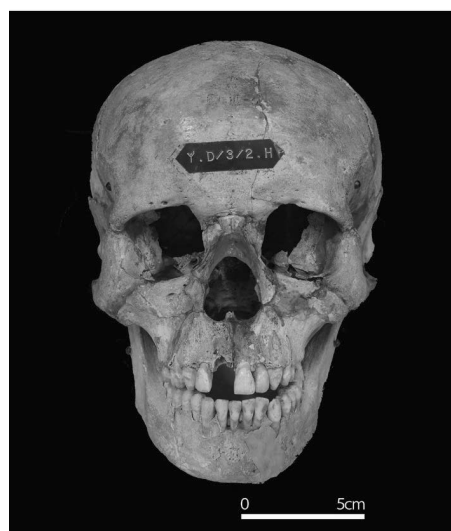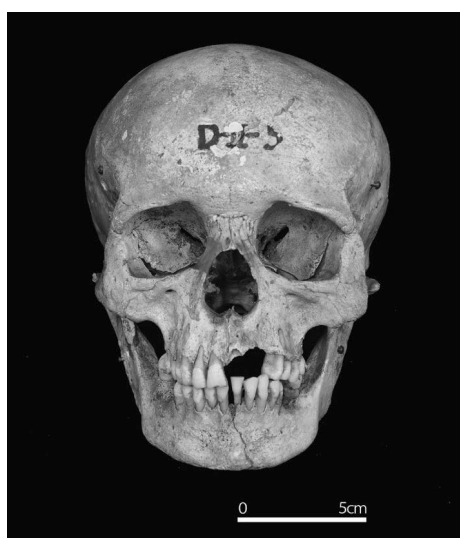
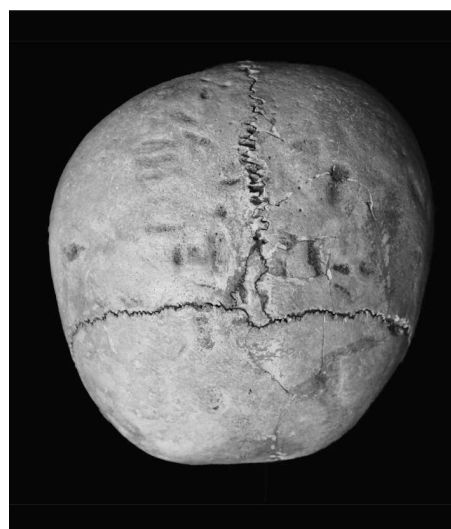
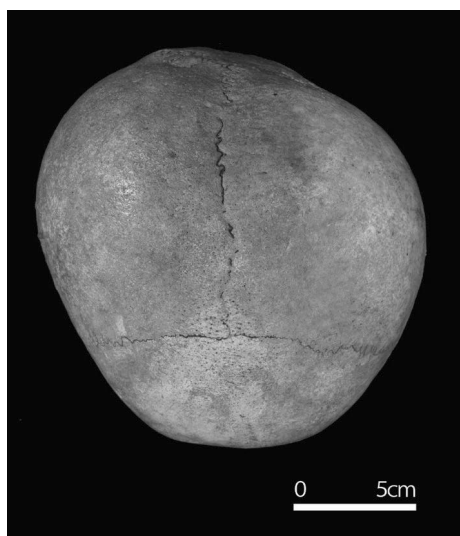


A 地区 11 号人骨



D I 地区 4b 号人骨

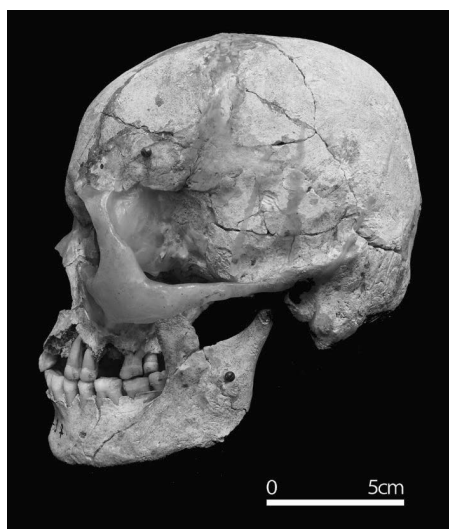
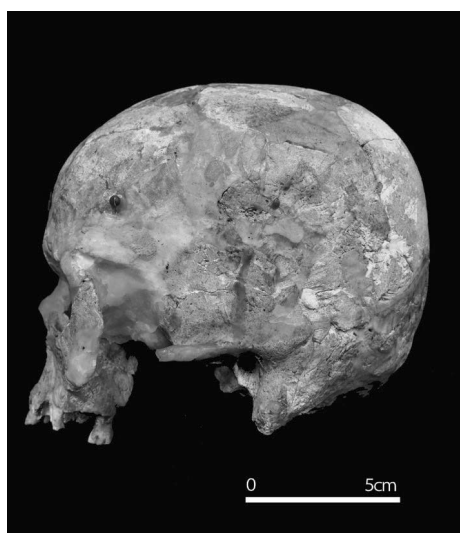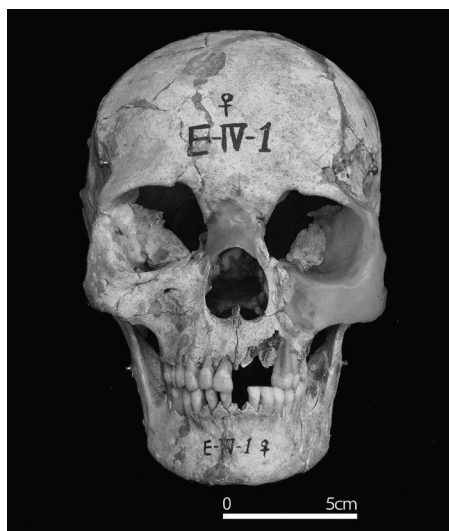
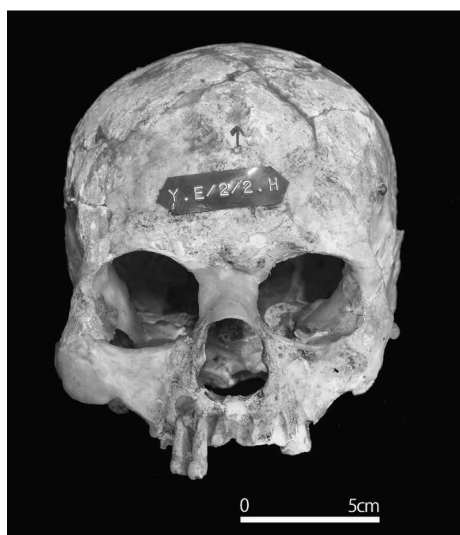
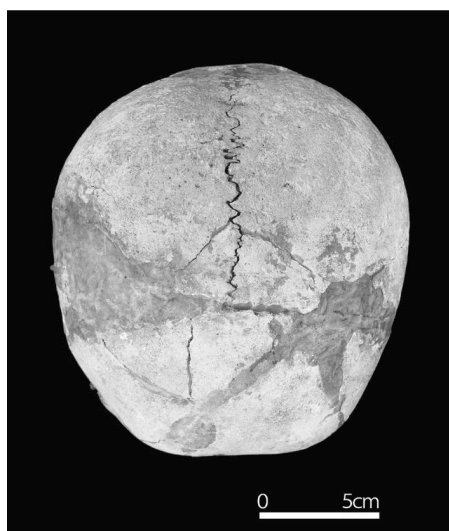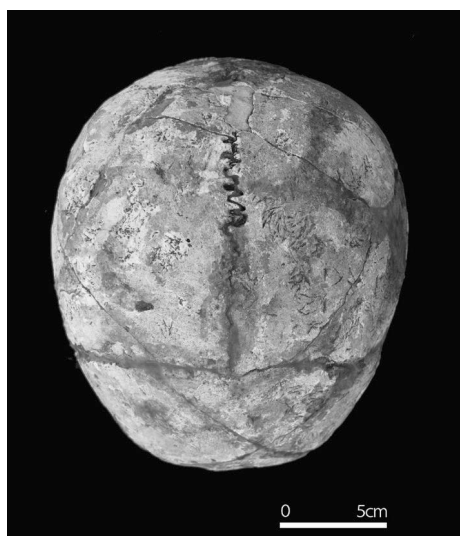写真 4



D II地区 5号人骨

D III地区 2号人骨

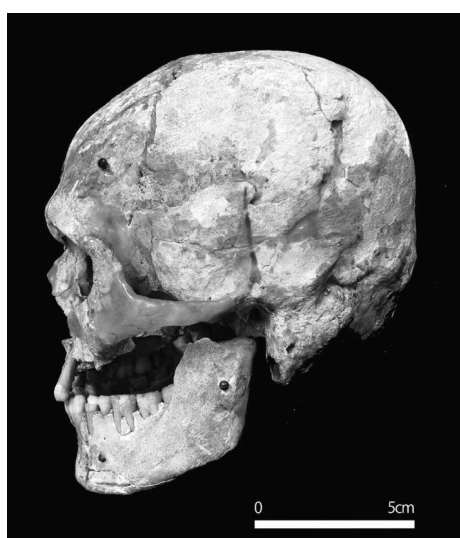
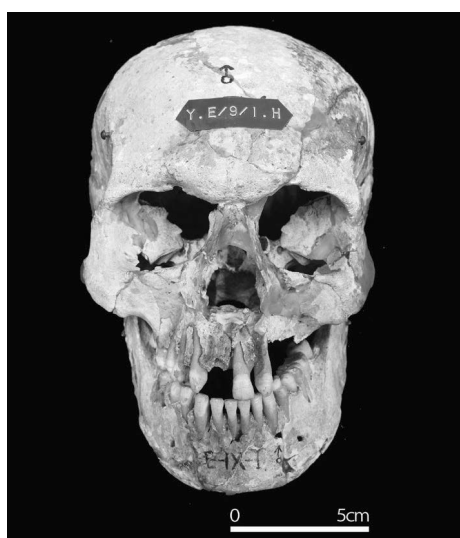

写真5



E II 地区 2 号人骨

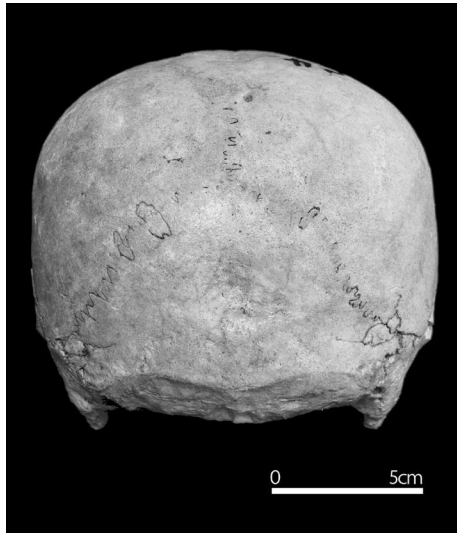
E IV 地区 1 号人骨

写真 6

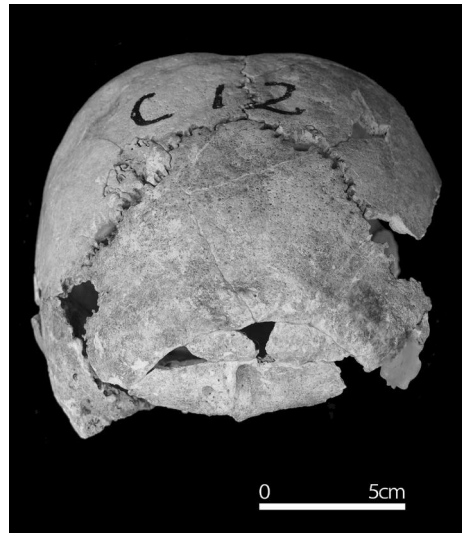

E IV地区 2号人骨

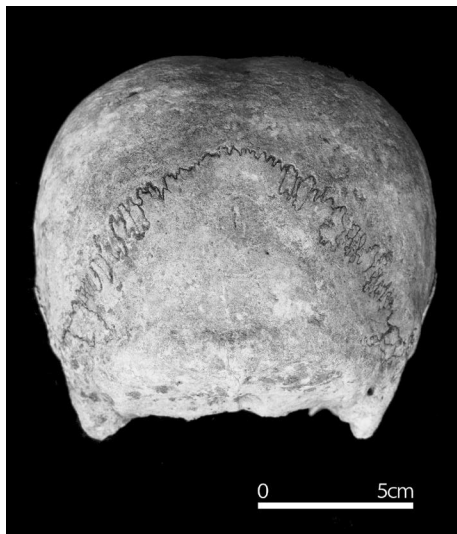
写真7



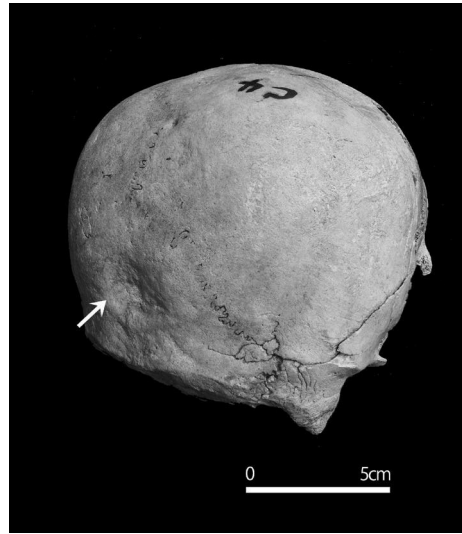
過剰縫合 (C地区4号人骨)



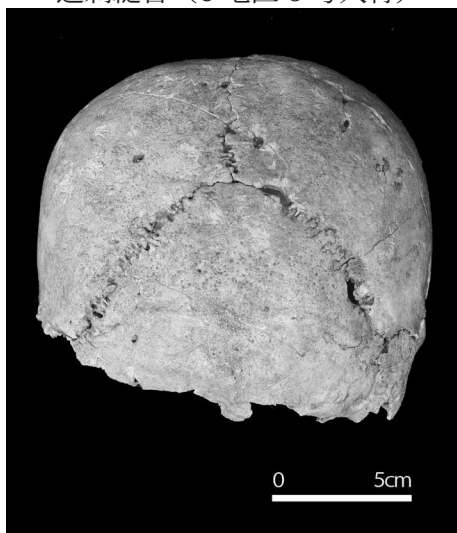
後頭骨の小孔 (C地区12号人骨)



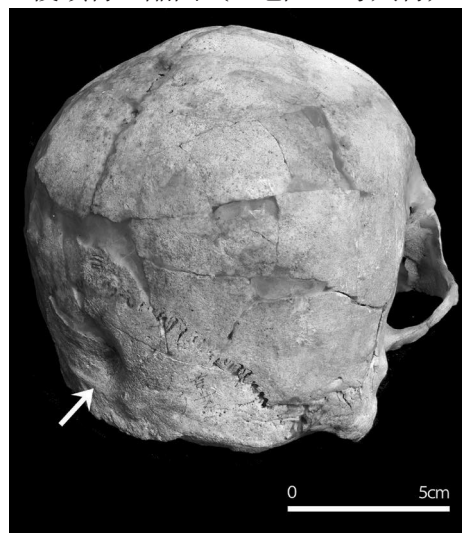
過剰縫合 (C地区6号人骨)



後頭骨の陥凹 (C地区4号人骨)

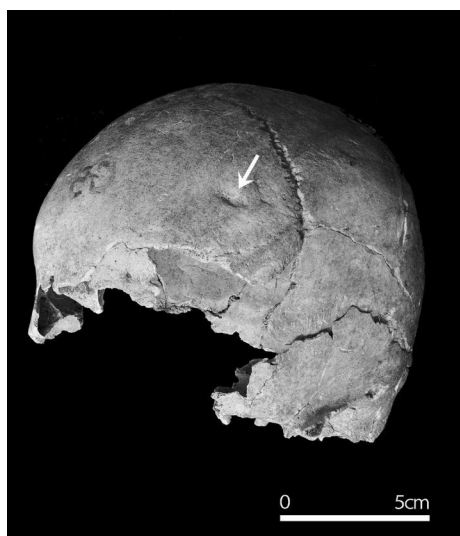

後頭骨の小孔 (C地区5号人骨)

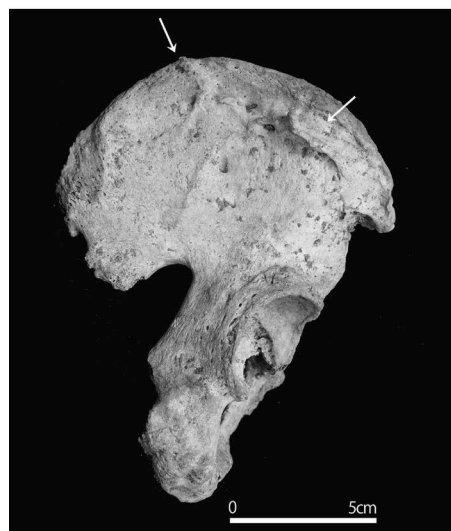

後頭骨の陥凹 (N2号西側人骨)

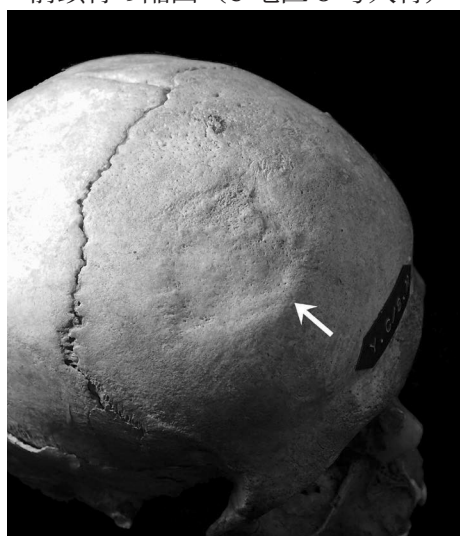
写真8



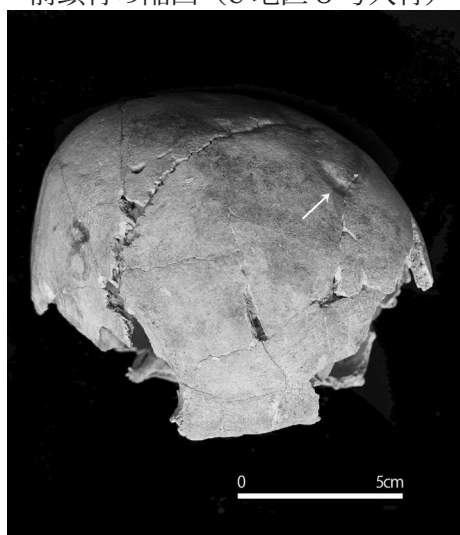
前頭骨の陥凹 (C地区5号人骨)



右側寛骨の骨折痕(C地区8号人骨)

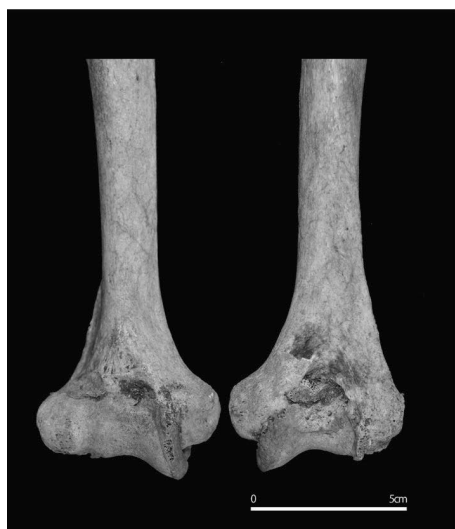

前頭骨の陥凹 (C地区8号人骨)

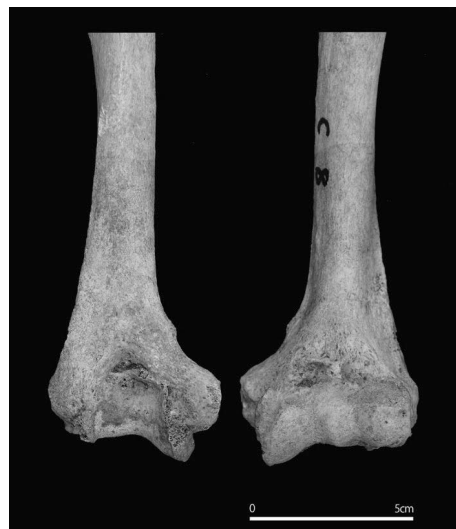

前頭骨の陥凹 (A地区8号人骨)

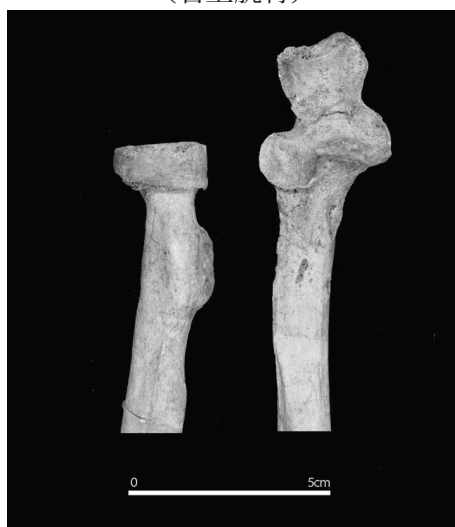写真9



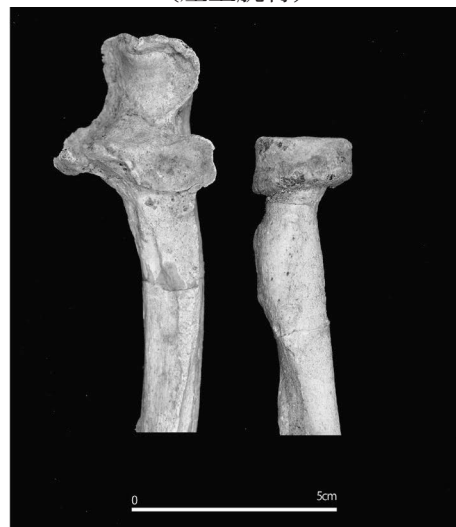(右上腕骨)



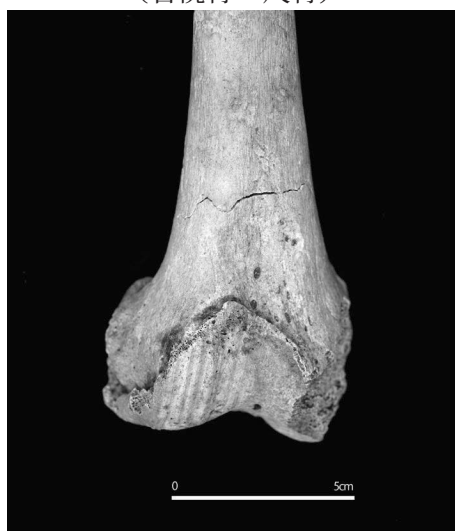(左上腕骨)



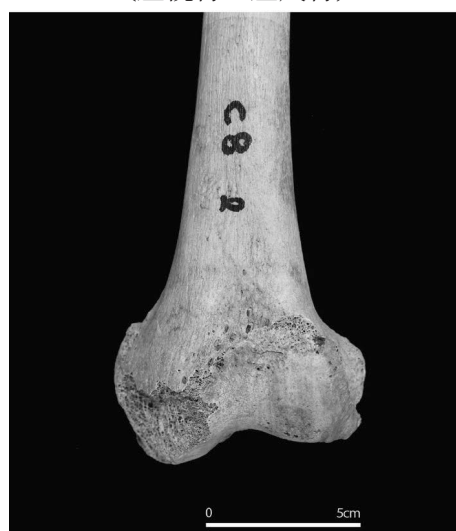(右橈骨・尺骨)



(左橈骨・左尺骨)



(右大腿骨)



(左大腿骨)

变形性関節症 (C 地区 8 号人骨)
写真10